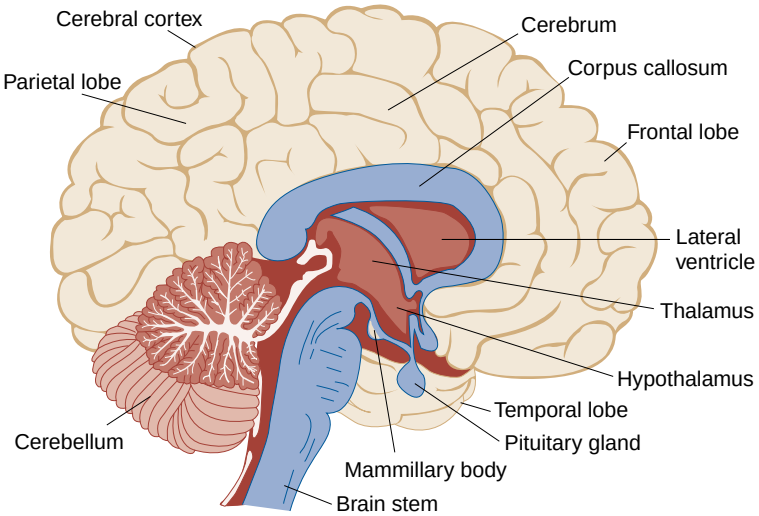
Cerebral cortex
Cerebrum
Parietal lobe
Corpus callosum
Frontal lobe
Lateral ventricle
Thalamus
Hypothalamus
Temporal lobe
Pituitary gland
Cerebellum
Mammillary body
Brain stem